



## PATIENT

Baldwin Zimmerman

## SPECIES

Feline

## BREED

Sphynx

## SEX

Male Neutered

## AGE

1.5 years

## WEIGHT

10lbs

## INTERPRETED BY

Maggie Machen Lamy,  
DVM, DACVIM  
(Cardiology)

## IMAGING PERFORMED BY

Lindsay Daniel,  
DVM

## PRESENTING CLINICAL SIGNS

History: Grade 4/6 systolic murmur. Some coughing reported.

## ECHOCARDIOGRAM FINDINGS

2D, m-mode, color flow and doppler imaging is available. The left ventricular wall is mildly hypertrophied with regions of irregularity. There is mildly hyperechoic endocardium consistent with fibrosis. Mild papillary muscle hypertrophy. The right ventricle is normal. There is mild left atrial enlargement present. No right atrial enlargement present. Normal RVOT velocity. Abnormal anterior motion of the mitral valve is present, with the tip visible in the LVOT during systole (see below). Elevated LVOT velocity is suspected. The anterior leaflet of the MV is mildly elongated and thickened, consistent with dysplasia. There is moderate eccentric mitral regurgitation present. No TR. No other obvious valvular regurgitation is present. No obvious intra or extracardiac shunts seen. There is no pericardial effusion noted. No pleural effusion appreciated.

## CARDIAC CHART

FELINE CARDIAC PARAMETERS	BODY WEIGHT (kg)	HR (BPM)	IVSd (cm) (Moise, Pipers)	LVIDd (cm) (Moise, Pipers)	LWVd (cm) (Moise, Pipers)	FS (%)	EF (%)
NORMAL PARAMETER	-----	150-240	0.35-0.55	<2 (mean 1.5)	3.5-0.55	35-67	80-100
PATIENT	4.5	230	0.68	1.4	0.63	56	89
FELINE CARDIAC PARAMETERS	LA/AO (Boon)	LA/AO HEART BASE (Swe) (Abbott)	LA 2D short axis Base view (cm) (Abbott)		LVOT VEL (m/s)	RVOT VEL (m/s)	E max (m/s)
NORMAL	<1.5	<1.3	<1.2		<1.6	<1.3	<0.9
PATIENT	1.2	1.5	1.5		1.7	1.0	NM
<p><i>*Note: All measurements based upon multi-modal images and methods. An average value is reported.</i>            Adapted from June Boon, Veterinary Echocardiography, 1998            Abbott J &amp; MacLean H JVIM 2006;20: 111-119, Moise et al. Am J Vet Res 47:1476, 1986. Pipers et al. Am J Vet Res 40:882, 1979.</p>							

## INTERPRETATION OF THE FINDINGS & FURTHER RECOMMENDATIONS

The diagnosis and cause of the murmur is mitral valve dysplasia leading to mild LV hypertrophy, moderate MR and an obstructive LVOT flow pattern. A primary HOCM component cannot be ruled out as a concurrent issue; however, it is less likely given the age of the patient. There is only mild left atrial dilation and mild LVH however, indicating the risk of spontaneous CHF and/or a thrombotic event is currently low.

While no medications have been shown to definitively alter long term outcome at this stage of disease, atenolol is often initiated to decrease the outflow obstruction. In cases of solely primary MV dysplasia this can lead to improvement in the degree of obstruction and hypertrophy. Given the young age of the cat and today's findings it is reasonable to initiate at this time as below.

Monitor at home for any respiratory signs, collapse or significant lethargy. **Structural disease is not suspected to be related to the cough, and baseline cough radiographs are recommended.**

## HOSPITAL NAME

Affordable Vet  
Services

## REFERRING VET

Dr. Rodriguez

## INVOICE

23254

## DATE

3/23/22



**PATIENT**

Baldwin Zimmerman

Long term prognosis is guarded given the age of the patient and highly variable nature of asymptomatic feline heart disease. Many cats will remain asymptomatic until mid-life or beyond, while others develop CHF within the first years. Close monitoring for progression to LA dilation in the future will help determine long term prognosis.

**SPECIES**

Feline

Anesthetic risk is considered mild, however judicious IV fluid rates are advised to avoid fluid overload. Additionally, drugs that stimulate heart rate should be avoided unless clinically necessary (glycopyrrolate, atropine). Avoid vasodilators as this may worsen the obstruction. A reasonable protocol includes opioid/benzodiazepine premedication, propofol induction, isoflurane maintenance. Additionally, steroids should be used with caution on older cats, as even a 'normal' geriatric heart can develop evidence of intolerance and fluid retention.

**BREED**

Sphynx

**SEX**

Male Neutered

**PLAN**

Baseline CXR to address the cough. Administer titrating dose of atenolol: 25mg tablets; Give ¼ tab once daily. Recheck heart rate in 1-2 weeks with target stressed rate of 140-160bpm 12-24 hours post-administration. Increase as needed until target reached. Screening blood pressure is recommended if possible.

**AGE**

1.5 years

Recommend recheck echocardiogram in 6 months to assess for progression and response to therapy, sooner if clinical issues arise.

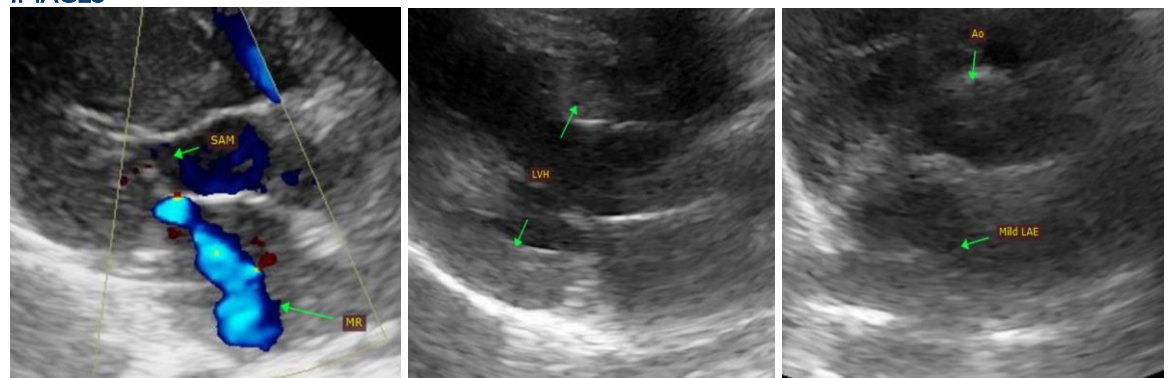
**WEIGHT**

10lbs

**IMAGES**

**INTERPRETED BY**

Maggie Machen Lamy,  
DVM, DACVIM  
(Cardiology)



**IMAGING PERFORMED BY**

Lindsay Daniel,  
DVM

**HOSPITAL NAME**

Affordable Vet  
Services

The information and recommendations provided are based on the images presented by the referring veterinarian. No evaluation can be communicated regarding pathology that was not visible in the image/video clips provided.

**REFERRING VET**

Dr. Rodriguez

Thank you for this referral. This report was generated using transcription software, and minor dictation errors may be present. If the clinical or image interpretation does not parallel your findings or if I can be of any further assistance, please contact me.

**INVOICE**

23254

**Maggie Machen Lamy, DVM**  
Diplomate of the American College of Veterinary Internal Medicine (Cardiology)  
info@sonopath.com

**DATE**

3/23/22



**PATIENT**

Baldwin Zimmerman

**SPECIES**

Feline

**BREED**

Sphynx

**SEX**

Male Neutered

**AGE**

1.5 years

**WEIGHT**

10lbs

**INTERPRETED BY**

Maggie Machen Lamy,  
DVM, DACVIM  
(Cardiology)

**IMAGING  
PERFORMED BY**

Lindsay Daniel,  
DVM

**HOSPITAL NAME**

Affordable Vet  
Services

**REFERRING VET**

Dr. Rodriguez

**INVOICE**

23254

**DATE**

3/23/22